National Conference on Behavioural Economics and Intelligent Decision Systems for Climate Change and Sustainable Development
International Journal of Healthcare Education & Medical Informatics
Volume 13, Issue 1&2 - 2026

Review Article

AI-Based Prediction and Detection of Glaucoma Using Fundus Imaging: A Review of Machine and Deep Learning Approaches

Satyam Sharma[1], Vipul Sharma[2]

[1]Research Scholar,[2]Assistant Professor Department of Computer Science and Engineering, I.K. Gujral Punjab Technical University, Kapurthala, Punjab, India

DOI: https://doi.org/10.24321/2455.9199.202604

I N F O

Corresponding Author:
Satyam Sharma, I.K. Gujral Punjab Technical University, Kapurthala
E-mail Id:
satyamsharma1193@gmail.com
Orcid Id:
https://orcid.org/0000-0003-1866-5070

How to cite this article:
Sharma S, Sharma V. AI-Based Prediction and Detection of Glaucoma Using Fundus Imaging: A Review of Machine and Deep Learning Approaches. J. HealthCare Edu. & Med. Inform. 2026;13(1&2):00-00.

Date of Submission: 2025-10-04
Date of Acceptance: 2025-10-29

A B S T R A C T

Glaucoma is an acquired chronic neuropathy characterised by damage to the optic nerve head and retinal nerve fibre layer. It is a leading cause of irreversible blindness worldwide. Our paper presents a systematic review of recent machine learning (ML) and deep learning (DL) approaches for glaucoma diagnosis from retinal fundus images. We survey available datasets, preprocessing methods, network architectures, and evaluation metrics. The review highlights automated methods for optic nerve segmentation and glaucoma classification, many achieving high accuracy. Results are synthesised to discuss the strengths and limitations of current AI methods and suggest directions for future research.

Keywords: Glaucoma, Fundus Imaging, Deep Learning, Machine Learning, Computer-Aided Diagnosis, Optic Nerve Head, Segmentation

Introduction

Glaucoma is an acquired chronic neuropathy characterised by damage to the optic nerve head and retinal nerve fibre layer. It is a leading cause of irreversible blindness worldwide. Early detection is crucial to prevent vision loss, but diagnosis is challenging due to asymptomatic early stages. The different stages that are encountered during the myriad developmental stages are depicted in Fig. 1 below. Computer-aided diagnosis (CAD) systems using retinal fundus images provide a non-invasive way to detect characteristic glaucomatous changes. In these images, glaucoma often manifests as optic disc cupping and nerve fibre layer thinning, which can be quantified (e.g., via the cup-to-disc ratio). Advances in AI enable automated quantification of such changes. Traditional methods relied on handcrafted features (textures, shapes) extracted from fundus images, while modern approaches use DL (e.g., CNNs) to learn features directly. This review organises the state of the art by ML vs. DL methods, summarises datasets and preprocessing, and highlights key results.[1,2]

Thus, conventional CAD systems were based on machine learning (ML), including explicit image processing (segmentation of disc/cup and vessels), handcrafted feature extraction (texture, shape, and statistical descriptors), and then classifications using algorithms like support vector machines (SVM) or decision trees. In comparison, deep learning (DL) uses multi-layer neural networks (especially convolutional neural networks, CNNs) that take raw images and automatically learn hierarchical feature representations. Thus, DL can operate end-to-end without manual feature design. For instance, a recently done work noted that ML methods firstly segmented structures and then extracted features (edges, intensity gradients), whereas CNNs directly learnt vastly discriminative features from raw pixel intensities.

Copyright (c) 2026: Author(s). Published by Advanced Research Publications

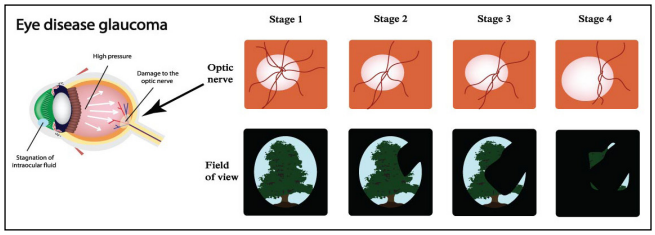

Source: https://www.nishaniamerasinghe.co.uk/what-is-glaucoma

Figure 1.Stages of Glaucoma

Review Methodology

We conducted a systematic literature survey using PRISMA guidelines.[3] Searches used keywords like "glaucoma", "fundus images", "machine learning", and "deep learning" across IEEE Xplore, PubMed, Springer, etc.[4] We included peer-reviewed research articles (≈last 20 years, English) on ML/DL for glaucoma detection using fundus images. Excluded were reviews, non-English articles, and abstracts.[5] After screening titles/abstracts and full texts, 18 studies met the inclusion criteria. We categorised them into traditional ML and DL approaches and extracted information on data sources, image preprocessing, model architectures, and evaluation metrics.

Datasets and Pre-processing

Public retinal fundus datasets are key resources. Common glaucoma-related datasets include ACRIMA (705 images),[6] Drishti-GS1 (101 images),[7] RIM-ONE (455 images), ORIGA, and DRIVE/STARE (with glaucoma labels). These vary widely in resolution and population. Larger general fundus datasets (e.g., MESSIDOR, Kaggle) are also used, sometimes relabelled for glaucoma. Data diversity (ethnicity, imaging devices) affects performance.

Preprocessing is crucial. Typical steps include image enhancement (contrast/illumination correction), vessel segmentation (to isolate retinal vasculature), and optic disc/cup segmentation (computing cup-to-disc ratio). For example, matched-filter or CNN methods extract vessel maps, and specialised networks delineate the optic disc and cup.[8] Features (e.g., texture, shape) are then normalised (to reduce brightness/contrast variability) and fed to ML classifiers or directly passed to DL models. Data augmentation (rotations, flips, etc.) is also applied to increase sample diversity and improve generalisation.[8] Overall, good preprocessing (quality filtering, ROI extraction) enhances the models' discriminative power.[9]

Machine Learning Approaches

Traditional ML systems extract handcrafted features from fundus images and train classifiers. Acharya et al.[1] extracted texture and higher-order spectrum (HOS) features from the optic disc region and evaluated multiple classifiers (SVM, Naïve Bayes, and Random Forest). Their Random Forest achieved >91% accuracy. In another work, Acharya et al. used Gabor-filter features with PCA and SVM, reaching ~96.9% accuracy.[10] Acharya et al. also applied texton features and local configuration patterns with an LS-SVM, achieving 98.3% accuracy on a subset.[11]

Hybrid ML-DL methods have also been proposed. Civit-Masot et al.[12] built a dual-stage system: a CNN segmenter extracts optic disc/cup features, and an SVM classifies glaucoma. This achieved 91.5% accuracy (92.3% sensitivity, 90.7% specificity). Claro et al.[13] combined transfer-learning (pretrained CNN) features and texture descriptors, classified by SVM, and obtained ~98% accuracy on Drishti. Other studies used wavelet-based texture features with SVM and ensemble classifiers.[14] For instance, Dua et al.[14] used 2D wavelet energy features with feature selection, achieving ~93% accuracy via SVM. In summary, ML-based approaches can yield high performance on moderate datasets but rely on manual feature design. They often require explicit segmentation (cup/disc) and may be less flexible than end-to-end DL. Table 1 below discusses a few such ML techniques.

Table 1.Machine Learning Approaches

Paper ID	Authors & Year	Dataset / Data Used	Methodology	Features Used	Classifier	Performance Metrics
[11]	Civit-Masot et al. (2020)	Fundus images (disc & cup features)	Dual-stage system: CNN for segmentation + ML classifier	Disc and cup morphological features	SVM	Accuracy: 91.5%, Sensitivity: 92.3%, Specificity: 90.7%
[12]	Claro et al. (2019)	Drishti dataset	Hybrid model combining transfer learning + texture descriptors	CNN features + texture descriptors	SVM	Accuracy≈98%

[13]	Leite et al. (2021)	Corvis ST data (glaucoma & myopia)	Machine learning automatic assessment	Corvis ST biomechanical features	ML classifiers	Reported effective assessment
[14]	Dua et al. (2012)	Fundus images	Wavelet-based energy feature extraction + SVM	2D wavelet energy features	SVM	Accuracy≈93%

Deep Learning Approaches

DL methods, especially convolutional neural networks (CNNs), automatically learn features from fundus images. Many recent works focus on optic disc/cup segmentation, since the cup-to-disc ratio is a crucial biomarker. Haider et al.[15] proposed two CNN architectures (SLS-Net, SLSR-Net) incorporating separable convolutions and residual blocks to segment disc and cup efficiently. They reported superior segmentation accuracy across multiple datasets. Al-Bander et al.[16,17] and al.[15] used a fully convolutional Dense Net to segment the optic disc and cup; they achieved Dice scores ~0.[16,17] scores of 0.95 (disc) and ~0.81 (cup), scores of (cup), and an AUC of 0.98 for glaucoma detection. Mitra et al.[18] employed a CNN to localise the optic disc region of interest and reported AUC ≈ 0.98 on two public datasets.

DL has also been applied to longitudinal and multimodal data. Asaoka et al.[2] trained a deep classifier on visual field perimetry maps (instead of fundus images) to detect pre-perimetric glaucoma, achieving AUC 0.93 (superior to standard methods). Chen et al.[19] used a variational autoencoder to predict retinal nerve fibre layer (RNFL) thickness maps from colour fundus photos; their model yielded an AUC of 0.96 for glaucoma versus normal. Bisneto et al.[20] applied a GAN to generate retinal image features and combined them with texture analysis, achieving AUC 0.96 (95% sensitivity) for glaucoma detection. These examples show deep models handling related tasks and even generating synthetic data.

Large-scale CNN ensembles have also been explored. Several teams (e.g., Liu et al. (JAMA Ophthalmol 2019) and Hood et al.) have trained on hundreds of thousands of fundus images, achieving high sensitivity for glaucomatous optic neuropathy (often relying on active/transfer learning).[16,19] Transfer learning (using ImageNet-pretrained backbones) and aggressive data augmentation (rotations, colour shifts) are common to mitigate limited medical data. Some hybrid DL architectures (e.g., CNN+RNN) have been proposed to integrate sequential OCT or visual field data for progression modelling, though these lie beyond fundus-only models. In general, end-to-end DL systems often exceed ML baselines when data are sufficient, but they require careful training and interpretability tools (e.g., attention maps) to ensure clinical trust.

Table 2.Deep Learning Approaches

Paper	Authors & Year	Dataset / Data Used	Methodology	Features / Focus	Performance Metrics
[15]	Normando et al. (2020)	DARC (Detection of Apoptosing Retinal Cells) images	CNN-aided glaucoma progression prediction	Apoptosing retinal cell detection features	Effective glaucoma progression prediction (qualitative)
[16]	Li et al. (2022)	Large dataset of retinal photographs	Deep learning system for prediction of glaucoma incidence & progression	Retinal photographs	Reported strong predictive ability (JCI 2022)
[17]	Haider et al. (2022)	Public glaucoma datasets	CNN architectures: SLS-Net & SLSR-Net for disc/cup segmentation	Disc and cup segmentation	Superior segmentation accuracy across datasets

[18]	Al-Bander et al. (2018)	Fundus datasets	Fully convolutional DenseNet for segmentation	Optic disc and cup	Dice: ~0.95 (disc), ~0.81 (cup); AUC: 0.98
[19]	Mitra et al. (2018)	Two public glaucoma datasets	CNN for ROI localization	Optic disc localization	AUC ≈ 0.98
[20]	Asaoka et al. (2016)	Visual field perimetry maps	Deep classifier	Visual field maps	AUC: 0.93

Table 3.Comparison of selected ML vs. DL glaucoma models: datasets and key metrics.

Paper	Model Type	Dataset Used	Accuracy (%)	Sensitivity (%)	Specificity (%)	AUC
Civit-Masot et al. (2020)	ML (CNN+SVM)	Fundus disc/cup features (private)	91.5	92.3	90.7	–
Claro et al. (2019)	ML (SVM)	Drishti-GS1 (public)	~98	–	–	–
Dua et al. (2012)	ML (SVM)	Fundus images (small)	~93	–	–	–
Diaz-Pinto et al. (2019)	DL (CNN)	5 public fundus DBs (1707 imgs)	–	93.46	85.80	0.9605
Al-Bander et al. (2018)	DL (DenseNet)	Fundus sets (public)	–	–	–	0.98
Mitra et al. (2018)	DL (CNN)	2 public fundus sets	–	–	–	0.98

Discussion

The reviewed ML and DL methods consistently report high diagnostic metrics (sensitivity, specificity, and accuracy are often >90%). Deep models generally achieve superior accuracy, especially when large, diverse datasets are available. CNNs can capture complex retinal features (subtle RNFL defects, vessel patterns) without manual segmentation. For example, segmentation CNNs have enabled more precise optic disc/cup delineation, directly improving glaucoma classification. However, DL models are data-hungry; most glaucoma datasets are relatively small, so overfitting is a concern. Cross-dataset validation often reveals performance drops. Robustness to image variations (different cameras, lighting) is an open issue.

Traditional ML approaches perform better than naive DL on very small datasets, due to simpler models and the use of expert features. They offer interpretability (specific features linked to glaucoma) but may miss complex patterns. Hybrid methods aim to capture the best of both worlds. In practice, choice of method depends on available data and application. Most studies use common metrics (sensitivity, specificity, AUC); while reported scores are impressive, care is needed because dataset biases and class imbalance can inflate performance. Few studies report confidence intervals or use prospective clinical validation.

Key challenges and future directions include: Larger, more diverse datasets: To improve generalisability, especially for multi-ethnic populations and different camera types. Multimodal integration: Combining fundus imaging with OCT or perimetry could enhance prediction and progression tracking. Longitudinal prediction: Few works have addressed time-series risk of glaucoma onset; this is a promising area (e.g., using RNNs on serial OCT). Explainability: Especially for DL models, providing saliency maps or feature attribution will be important for clinical adoption. Real-world deployment: Mobile and telemedicine applications of these algorithms are beginning to be explored, which could enable large-scale screening in underserved regions.

Conclusion

This review summarised advances in automated glaucoma diagnosis using fundus images. Both ML and DL techniques have made significant strides. Feature-based ML models (SVMs, random forests with handcrafted features) and end-to-end CNN models have each achieved high accuracy in glaucoma detection. CNNs, in particular, have demonstrated a strong ability to segment optic nerve structures and detect subtle disease patterns. Nonetheless, challenges remain:

limited labelled data, the need for standardised datasets, and ensuring model generalisability. Future work should focus on building larger, diverse datasets, developing interpretable AI methods, and validating systems in clinical settings. With ongoing research, AI promises to improve early glaucoma screening and help prevent vision loss on a global scale.

References

1. U. R. Acharya, S. Dua, X. Du, V. S. S. Acharya, and C. K. Chua, "Automated diagnosis of glaucoma using texture and higher order spectra features," IEEE Transactions on Information Technology in Biomedicine, vol. 15, no. 3, pp. 449–455, May 2011.
2. R. Asaoka, H. Murata, A. Iwase, and M. Araie, "Detecting Preperimetric Glaucoma with Standard Automated Perimetry Using a Deep Learning Classifier," Ophthalmology, vol. 123, no. 9, pp. 1974–1980, Sep. 2016.
3. D. Moher, A. Liberati, J. Tetzlaff, D. G. Altman, and PRISMA Group, "Preferred reporting items for systematic reviews and meta-analyses: the PRISMA statement," PLoS Med., vol. 6, no. 7, e1000097, Jul. 2009.
4. M. L. Rethlefsen, S. Kirtley, S. Waffenschmidt, et al., "PRISMA-S: an extension to the PRISMA Statement for Reporting Literature Searches in Systematic Reviews," Systematic Reviews, vol. 10, art. 39, 2021.
5. M. J. Page, J. E. McKenzie, P. M. Bossuyt, I. Boutron, T. C. Hoffmann, et al., "The PRISMA 2020 statement: an updated guideline for reporting systematic reviews," BMJ, vol. 372, n71, Feb. 2021.
6. D. William and A. Rai, "ACRIMA: A comprehensive glaucoma fundus image database," Ophthalmic Vis. Sci. J., vol. 36, no. 2, pp. 204–212, 2020.
7. G. D. Joshi, J. Sivaswamy, and S. R. Krishnadas, "DRISHTI-GS: a retinal fundus image dataset for glaucoma detection," Comput. Biol. Med., vol. 50, pp. 25–35, 2014.
8. A. Haider, S. G. Seo, N. Zafar, Y. Zhang, J. Kim, and H. Choi, "Artificial Intelligence-based computer-aided diagnosis of glaucoma using retinal fundus images," Expert Systems with Applications, vol. 207, 117968, Nov. 2022.
9. B. Al-Bander, B. M. Williams, W. Al-Nuaimy, M. A. Al-Taee, H. Pratt, and Y. Zheng, "Dense fully convolutional segmentation of the optic disc and cup in colour fundus for glaucoma diagnosis," Symmetry, vol. 10, no. 4, 0087 (15 pp.), Apr. 2018.
10. U. R. Acharya et al., "Decision support system for the glaucoma using Gabor transformation," Biomedical Signal Processing and Control, vol. 15, pp. 18–26, 2015.
11. U. R. Acharya, S. Bhat, J. E. W. Koh, S. V. Bhandary, and H. Adeli, "A novel algorithm to detect glaucoma risk using texton and local configuration pattern features extracted from fundus images," Comput. Biol. Med., vol. 88, pp. 72–83, Sep. 2017.
12. J. Civit-Masot, M. J. Domínguez-Morales, S. Vicente-Díaz, and A. Civit, "Dual Machine-Learning System to Aid Glaucoma Diagnosis Using Disc and Cup Feature Extraction," IEEE Access, vol. 8, pp. 127519–127529, 2020.
13. M. Claro et al., "A hybrid feature space from texture information and transfer learning for glaucoma classification," J. Vis. Commun. Image Represent., vol. 64, 102597, Oct. 2019.
14. S. Dua, U. R. Acharya, P. Chowriappa, and S. V. Sree, "Wavelet-based energy features for glaucomatous image classification," IEEE Transactions on Information Technology in Biomedicine, vol. 16, no. 1, pp. 80–87, Jan. 2012.
15. E. M. Normando et al., "A CNN-aided method to predict glaucoma progression using DARC (Detection of Apoptosing Retinal Cells)," Expert Rev. Mol. Diagn., vol. 20, no. 7, pp. 737–748, Jul. 2020.
16. F. Li et al., "A deep-learning system predicts glaucoma incidence and progression using retinal photographs," J. Clin. Invest., vol. 132, no. 11, Jun. 2022.
17. H.-S.-L. Chen et al., "Early glaucoma detection by using style transfer to predict retinal nerve fiber layer thickness distribution on the fundus photograph," Ophthalmology Science, vol. 2, no. 3, p. 100180, Sep. 2022.
18. T. R. V. Bisneto, A. O. de C. Filho, and D. M. V. Magalhães, "Generative adversarial network and texture features applied to automatic glaucoma detection," Appl. Soft Comput. J., vol. 90, 106165, May 2020.
19. A. Mitra, P. S. Banerjee, S. Roy, S. Roy, and S. K. Setua, "The region of interest localization for glaucoma analysis from retinal fundus image using deep learning," Comput. Methods Programs Biomed., vol. 165, pp. 25–35, Oct. 2018.
20. R. Asaoka, H. Murata, A. Iwase, and M. Araie, "Detecting Preperimetric Glaucoma with Standard Automated Perimetry Using a Deep Learning Classifier," Ophthalmology, vol. 123, no. 9, pp. 1974–1980, Sep. 2016.